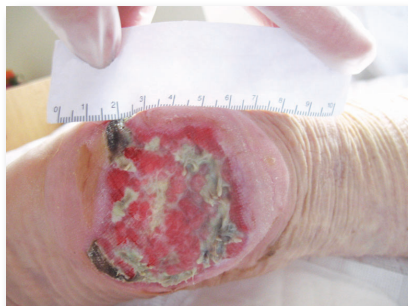
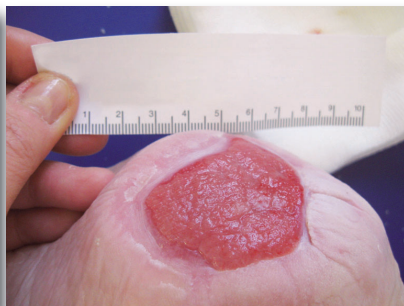
Photo Gallery

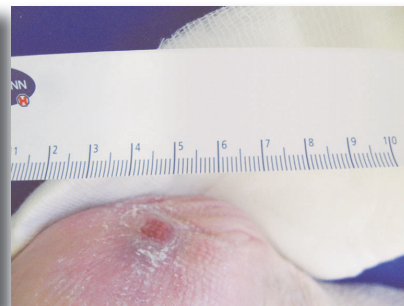
Female, born in 1927, ulcer decubitus, left heel:



before HemaGel® application
3 December 2008

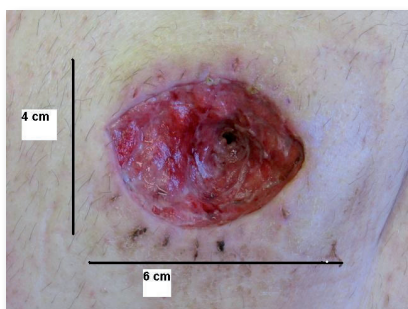


after HemaGel® application
8 January 2009

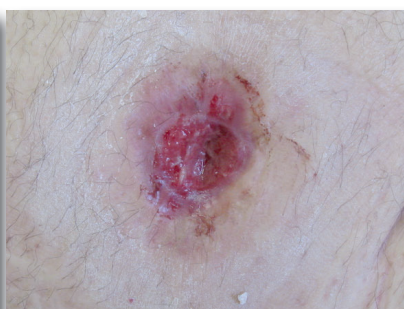

after HemaGel® application
6 February 2009

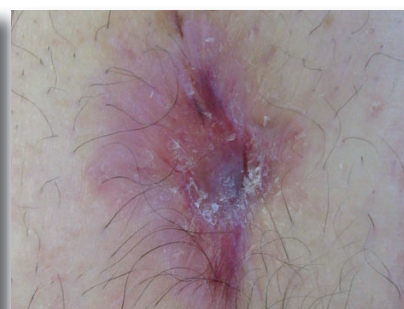Male, born in 1947, diabetic on insulin, ileostomy:



before HemaGel® application
1 December 2008

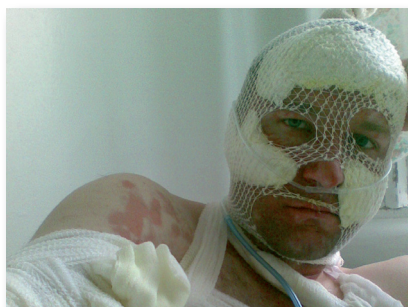

after HemaGel® application
2 January 2009

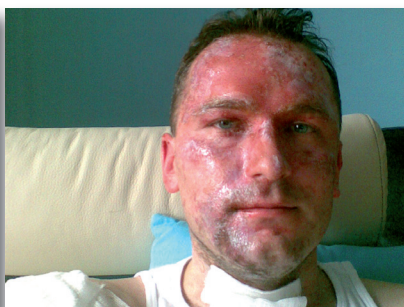

after HemaGel® application
6 February 2009


Healing process using HemaGel®:



before HemaGel® application

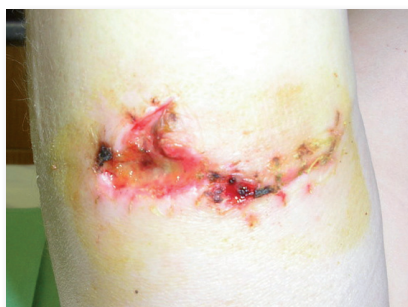

after HemaGel® application
Day 3

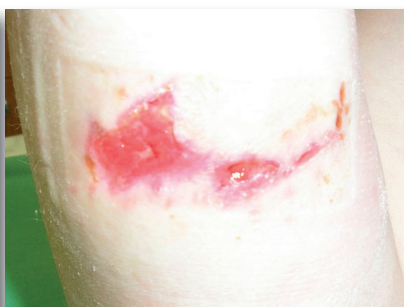

after HemaGel® application
Day 5

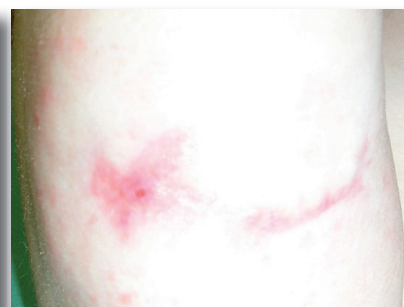Female, born in 1970, bitten by a dog:



before HemaGel® application
18 March 2008



after HemaGel® application
27 March 2008



after HemaGel® application
15 April 2008